

## *Growth and Development: Dynamic Long-Term Change*

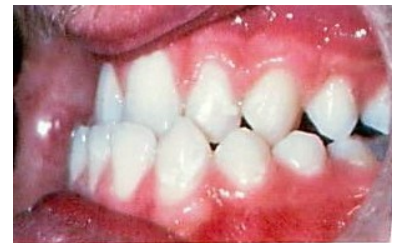For years baseball players have been telling golfers that baseball is the more difficult sport since it involves hitting a moving target. Orthodontics has similar analogy. Though treatment of a young patient may be underway, additional growth and development can change the position of the patient's teeth. The dentofacial complex or "target," therefore, is changing or "moving", but at a much slower rate. Drs. Arthur B. Lewis and Alex F. Roche, both of the Wright State University School of Medicine, suggest that there are small but real increments of growth in the cranial base and mandible into the third decade. Dr. Rolf Behrents, of the University of Tennessee's Department of Orthodontics, has shown that craniofacial growth changes after 17 years of age are small but do indicate evidence of continued remodeling throughout life. This subtle, slow change can often affect the soft tissue profile as well as the position of the teeth. Satisfactory growth and development are most often evident when there are favorable morphogenetic factors present. These factors, coupled with normal environmental conditions, contribute heavily toward a normal range of growth and development.

rate.

### **Early Recognition is Important**

When the skeletal relationships are not within the accepted range of variation, teeth tend to change their position to adjust to the discrepancy. This is nature's way of attempting to treat a malocclusion. This dental compensation often helps to hide a more severe skeletal discrepancy and points out the importance of cephalometric analysis as an adjunct to the clinical examination and other records. Examples of dental compensations are often seen in skeletal Class II Division 1 relationships when the mandibular incisors tend to be tipped labially. ( Fig 3)

In skeletal Class III relationships, the mandibular incisors are usually tipped lingually to help offset the existing skeletal imbalance. ( Fig 1) The teeth often continue to move in this manner as skeletal relationships become more severe with unfavorable growth and development.



**Fig 1: Notice mandibular incisors are tipped lingually in Class III patients.**

### Early detection of poor skeletal relationships and their concomitant dental compensations is important.

A first phase of treatment is often beneficial in these severe malocclusions. Appropriate fixed and/or removable orthopedic appliances, combined with favorable growth and development and patient cooperation, can improve skeletal relationships and diminish skeletal malocclusions. ( Fig 4) Decompensating tooth positions also improves gingival soft tissue conditions.

Teeth that are tipped excessively place undue stress on supporting bone and soft tissue, contributing to gingival recession and thinning of the alveolar support. Successful treatment of severe malocclusions within a two-year period can be difficult. A first phase of treatment, therefore, is usually designed to improve the malocclusion, not necessarily to correct it completely. ( Fig 2)

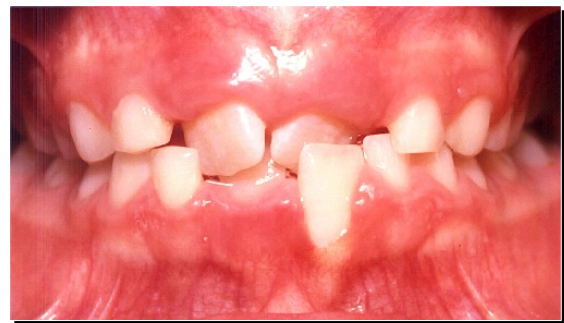### Static vs. Dynamic Analysis- Thinking Long-Term

The severity of a malocclusion is best determined by an early evaluation of a complete set of diagnostic records. The initial set of records allows for a static analysis at one point in time. The clinical examination, models, radiographs, photographs and patient history all help to assess the need for orthodontic treatment.

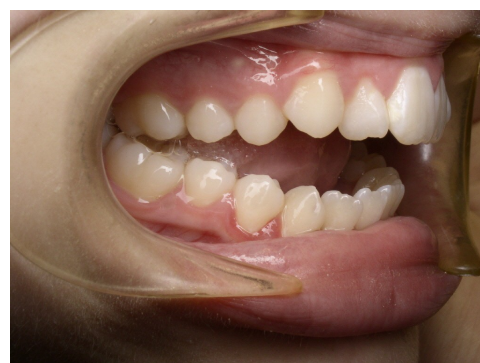A dynamic analysis of malocclusion involves assessments of the problem at two or more points in time. This may involve taking progress records to show what changes may have occurred from treatment and/or growth and development.

Variations in the skeletal, dental and soft tissue relationships are evaluated better over a period of time with progress records. Genetic and environmental factors also are better assessed over time.

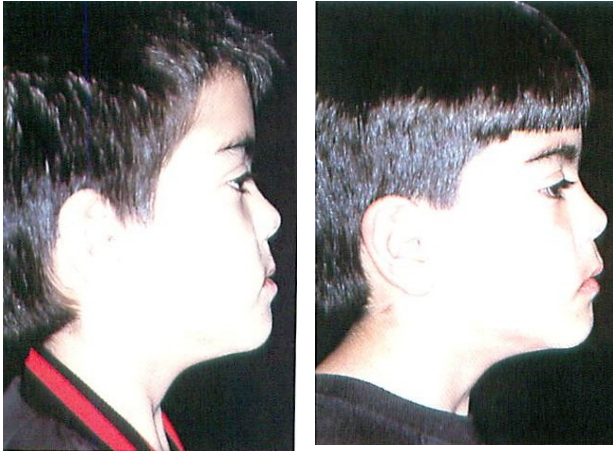
Long-Term analysis also includes consideration of third molars, additional growth and development, limited retention vs. permanent retention and continued functional problems. These factors often affect the long-term stability of orthodontic treatment.



**Fig 2:** Notice recession of mandibular incisor due to anterior crossbite. Decompensating this will automatically improve the health of the gingiva.



**Fig 3:** Note the lower incisors are tipped labially in Class II patients to compensate for the malocclusion.



**Fig 4: Early detection helps correct poor skeletal relationships—Class III profile corrected.**

### Growth Timing in a Changing Mouth

Diagnostic records, frequently taken long before treatment is needed, aid in determining the best treatment timing. Correct treatment timing can help achieve the maximum result with the minimum amount of both chair time and involvement in appliance therapy.

As stated earlier, dentofacial change occurs naturally in both treated and untreated individuals. Children have faces that are usually fuller and more convex than adults. Study of malocclusion includes assessment of the normal range of variation, as well as the patient's age, sex, and racial traits.

Dr. Donald Woodside, of the University of Toronto's Department of Orthodontics, has shown three peak velocity growth curves in the mandible for males and females. These curves vary in amplitude and timing, depending on sex. This type of information is beneficial in properly timing orthodontic or orthopedic intervention.

### Relative Stability vs. Absolute Stability

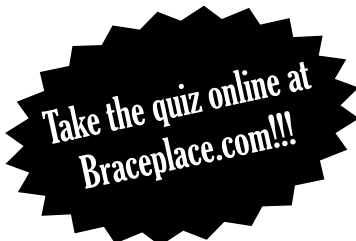Ongoing research seeks to determine how to minimize the long-term changes that occur naturally. Follow-up studies of treated cases have shown that some natural change of tooth position is common. Just as all other tissues of the body turn over and change with age, so do the bones of the dentofacial complex.

One often wishes that bone could be transformed into stone once orthodontic treatment is completed. However, continued detrimental oral habits, functional problems as mouth breathing, continued growth and development, and muscle function can all affect long-term stability.

The more we understand the changes that occur both naturally and following all types of dental treatment, the better the service we can render to our patients.

#### References

1. Lewis AB, Roche AF. Late growth changes in the craniofacial skeleton. *Angle Ortho* 1988; 58:127-35.
2. Behrents RG. Growth in the aging craniofacial skeleton; Monograph 17; 121. Craniofacial Growth Series. Center for Human Growth and Development, Univ. of Michigan; 1985a.



### **Orthodontic Update Continuing Education Credit**

Orthodontic Update Continuing Education program is designed for the general dentist, dental specialist, and staff members. Readers can earn 2 hours of continuing education credit for each issue. Here's how it works:

1. Read the issue of Orthodontic Update
2. Complete the quiz and return it to the Freehold office. Copies of the quiz will be accepted. **No fee is required.**
3. Upon receipt The Brace Place will process the quiz and issue a continuing education credit report. To facilitate learning through self-instruction, correct answers will be published in the following issue.

Two hours of credit will be awarded for completing this quiz. Continuing education requirements vary from state to state. According to the New Jersey State Board of dentistry, a limit exists on the number of eligible credit hours from a home study course:

- |           |                          |
|-----------|--------------------------|
| Dentists: | 10 Credits every 2 years |
| RDA:      | 4 Credits every 2 years  |
| RDH:      | 4 Credits every 2 years  |
| CDA:      | Unlimited                |



**Our next issue will  
ONLY BE AVAILABLE AT OUR WEBSITE:  
Braceplace.com**

# Q U I Z

- |    |     |  |
|----|-----|--|
| 1. | T F | An example of dental compensation is when the mandibular incisors are tipped labially in a Class II, Div 1 relationship. |
| 2. | T F | A static analysis is one that occurs over a long time.   |
| 3. | T F | A dynamic analysis occurs at one point in time.  |
| 4. | T F | Dentofacial changes occur naturally in both treated and untreated individuals.   |
| 5. | T F | Dental compensations often hides a more severe skeletal discrepancy.   |